

Tibiofemoral movement 1: the shapes and relative movements of the femur and tibia in the unloaded cadaver knee

H. Iwaki, V. Pinskerova, M. A. R. Freeman
From the Charles University, Prague, Czech Republic

In six unloaded cadaver knees we used MRI to determine the shapes of the articular surfaces and their relative movements. These were confirmed by dissection.

Medially, the femoral condyle in sagittal section is composed of the arcs of two circles and that of the tibia of two angled flats. The anterior facets articulate in extension. At about 20° the femur 'rocks' to articulate through the posterior facets. The medial femoral condyle does not move anteroposteriorly with flexion to 110°.

Laterally, the femoral condyle is composed entirely, or almost entirely, of a single circular facet similar in radius and arc to the posterior medial facet. The tibia is roughly flat. The femur tends to roll backwards with flexion.

The combination during flexion of no antero-posterior movement medially (i.e., sliding) and backward rolling (combined with sliding) laterally equates to internal rotation of the tibia around a medial axis with flexion. About 5° of this rotation may be obligatory from 0° to 10° flexion; thereafter little rotation occurs to at least 45°. Total rotation at 110° is about 20°, most if not all of which can be suppressed by applying external rotation to the tibia at 90°.

*J Bone Joint Surg [Br] 2000;82-B:1189-95.
Received 29 October 1999; Accepted 7 January 2000*

The shapes and movements of the femur and tibia as they articulate in the knee have been the subject of anatomical description and debate since 1836. The literature is by now too extensive to review fully. It is cited more completely elsewhere¹ and will be on the JBJS web site (www.jbjs.org.uk) for this issue of the Journal until 2002. Early publications from Weber and Weber² to Strasser³ are in German

(or in one case French) and are largely unknown and unreferenced.

We have examined the non-weight-bearing cadaver knee throughout its range of flexion, extension and longitudinal rotation using MRI. Subsequently, the specimen was dissected in order to confirm our interpretation of the MR images. This investigation offers three advantages compared with dissection alone or radiography. First, the relative positions and shapes of the bones and cartilage in the intact medial and lateral compartments can be established separately but simultaneously at each increment of flexion, a fact crucial to a description of the movement of the knee. Secondly, the menisci and cruciate ligaments can be imaged while the knee is moved with the capsule intact, and thirdly, MRI can be applied without risk to the living knee.

In this paper we describe the shapes of the bones in sagittal section and the relative position of the condyles both medially and laterally at certain points in the flexion cycle. It is then possible to deduce the nature of the rotations and translations which occur between the two bones. In principle, this knowledge can be applied to the living knee, as examined by MRI.

Materials and Methods

Specimens were obtained by sectioning the femur and the tibia 15 cm from the joint line without opening the capsule. In total, 24 knees were imaged and dissected to develop the technique described below or to obtain supplementary information. Six knees were fully imaged for this study. All were from men with a mean age of 43 years (25 to 55). Five were right-sided. None showed abnormalities other than fibrillation of the cartilage.

The knee was attached to a wooden board with the medial side downwards. The joint itself lay opposite a space cut so that the knee could be viewed from all its aspects. Two non-metallic pegs were driven through drill holes in the tibia into the board. The knee was then fully extended using manual force equivalent to that which might be applied on clinical examination. Two drill holes were made through the femur into the board. Pegs were then passed through these holes to fix the femur. This sequence was repeated at intervals of flexion up to 120° using light

H. Iwaki, MD, Orthopaedic Surgeon
V. Pinskerova, MD, Consultant Orthopaedic Surgeon
M. A. R. Freeman, MD, FRCS, Honorary Consultant Orthopaedic Surgeon

Correspondence should be sent to Mr M. A. R. Freeman at The Bone and Joint Research Unit, The Royal London Hospital, Whitechapel Road, London E1 1BB, UK.

©2000 British Editorial Society of Bone and Joint Surgery
0301-620X/00/810717 \$2.00

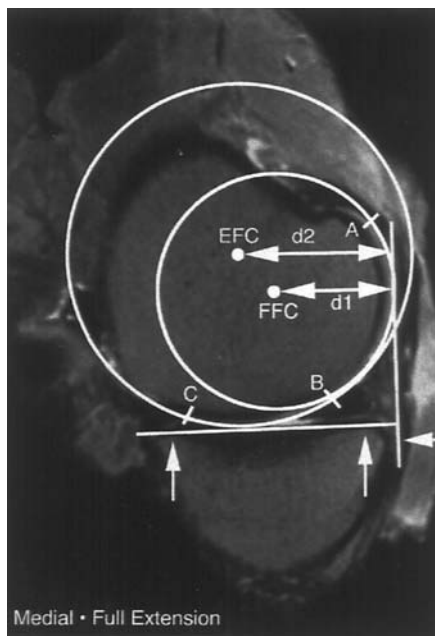


Fig. 1a

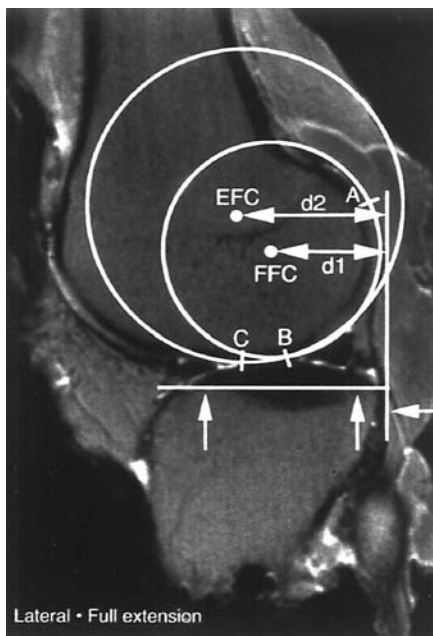


Fig. 1b

Medial and lateral sagittal MR images with circular templates placed over the posterior (A-B) and anterior (B-C) segments of the femoral articular surfaces. (The fit of a circle to the small lateral anterior segment is uncertain.) We have called the posterior segment the 'flexion facet' and the anterior the 'extension facet'. Their centres are labelled FFC and EFC respectively. The distances d_1 and d_2 from the ipsilateral posterior tibial cortices (arrowed) to the FFC and EFC were measured as described in the text and are shown at various degrees of flexion and rotation in Figures 5, 6 and 7.

finger pressure to position the femur. The latter was rotated into full external rotation at 90° and internal rotation at 45° , 90° , 110° and 120° using manual force comparable to that applied in full extension.

The specimen was then transferred to a Gyroscan MRI scanner (Philips Medical Systems, Eindhoven, The Netherlands). Multistack slices in the sagittal, coronal and frontal planes were obtained with the following sequence parameters: THR, 234 ms; TE, 90 ms; and flip angle, 90° . We used sagittal images through the medial and lateral tibiofemoral compartments, orientated as closely as possible perpendicular to the posterior femoral condylar cortices in full extension and at each of the chosen positions of flexion and longitudinal rotation. On average, the medial slice was 12 mm and the lateral slice 59 mm from the medial tibial cortex.

By using acetate overlays marked with circles of various diameters, two observers independently identified an anterior and a posterior circular surface on the femoral condyles (Fig. 1). The intra- and interobserver errors with respect to the location of the centres of these circles were estimated as follows. Ten images were selected at random. These were measured three times by two observers (HI and VP) independently with a minimum interval of one day between measurements. Intraclass correlation was 98.9%, showing the high reproducibility of this method of measurement. When one measurement was taken by the two independent observers, the standard deviation was 0.77 mm and the 95% confidence interval was 1.51 mm. Some of our other measurements may have greater errors but we have not quantified them. The exact measurement of biological features is difficult: 'flat' surfaces are not truly flat; 'circles' are not perfectly circular; 'points' are hard to define. Thus, the

nature of the material does not support the level of accuracy that would be appropriate in engineering science.

The radii and angular arcs of the femoral circles were measured medially and laterally (Fig. 2). The arc subtended by that portion of the posterior femur which articulates only with the posterior horn in full flexion and never with the tibia, was also measured.

The medial and lateral tibial articular surfaces were subdivided into certain areas as shown in Figure 2. We measured the angle between two of the surfaces (EF and FF) on the medial side and the lengths of all segments.

The distances between the ipsilateral posterior tibial cortex and the centre of the posterior femoral circles (d_1 in Figure 1) at each position were measured by drawing a line through the most proximal points in the medial and lateral tibial subchondral bone signals (arrowed in Figure 1). A second line perpendicular to the first was drawn as a tangent to the posterior tibial cortex. The distance d_1 was measured perpendicularly from this second line. Distances were corrected for magnification. A similar sequence was carried out with respect to the anterior circle of the medial femoral condyle (d_2 in Figure 1a). On the lateral side the arc subtended by the anterior circle was defined anteriorly as being limited by the posterior border of the anterior horn in full extension. This arc could be found, but not with certainty because of its small extent, in only four of the six knees. One knee extended only to 5° flexion and in another the posterior circle appeared to extend anteriorly to reach the anterior horn, i.e. there appeared to be no anterior arc. The centre of this arc is therefore marked '?' in Figure 2. **Principle of the measurements.** The principle for the determination of tibiofemoral movement was suggested by the work of Weber and Weber.² The two 'wheels' in Figure

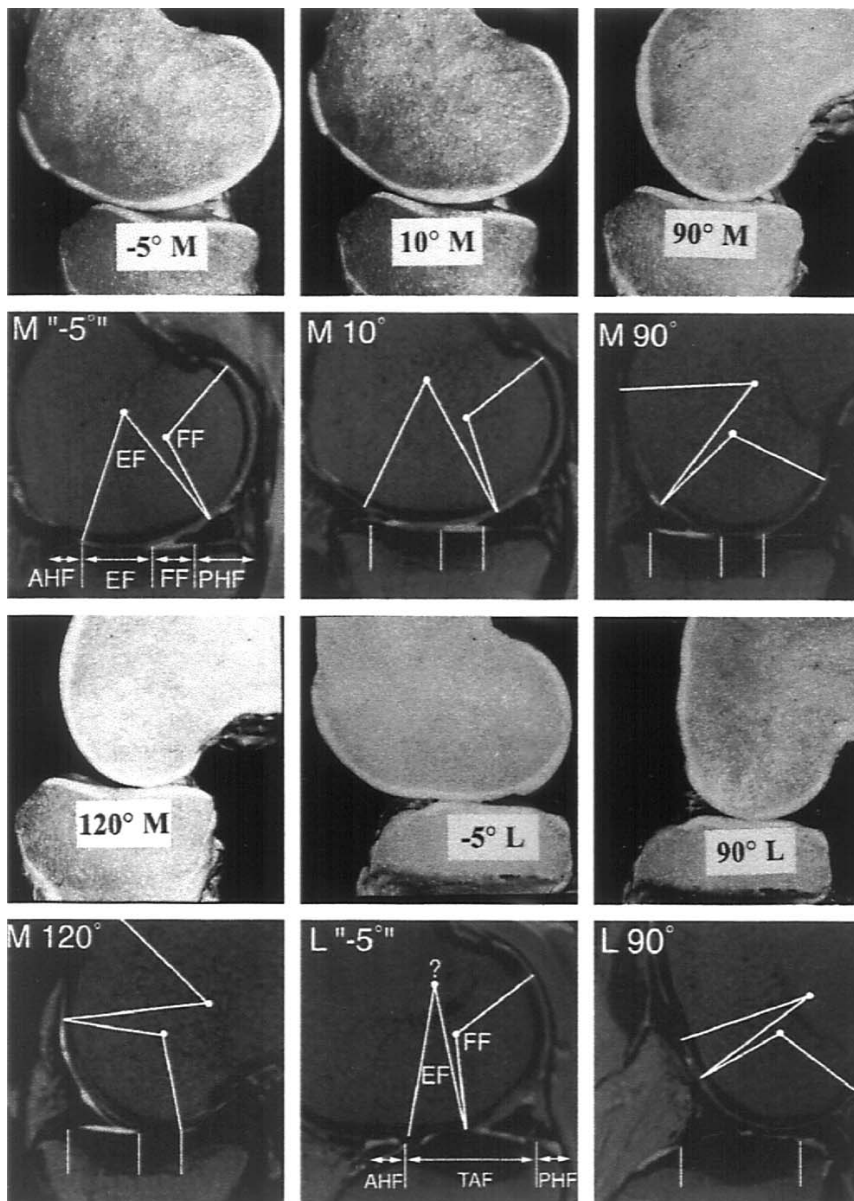


Fig. 2

Sagittal sections and the corresponding MR images made with the capsule intact of: the medial compartment (M) at full extension -5° , 10° , 90° and 120° ; and the lateral compartment (L) at -5° and 90° . The appearance of the dissections and of the MR images is the same. The femoral facets (shown in Figure 1) and the tibial facets (described in the text) are identified medially and laterally on the MR images at -5° and are outlined, but not labelled, on the remaining four MR images.

EF: extension facet
 FF: flexion facet
 AHF: anterior horn facet
 PHF: posterior horn facet
 TAF: (lateral) tibial articular facet

3 (top) are composed of the arcs of two circles with centres at A and B. The white rod is fixed to these centres. This rod represents the 'geometrical axis' (i.e. the imaginary axle) for the arc of rotation during which the surfaces a and b are in contact with the plane. When the circular surfaces c and d contact the plane the 'geometrical axis' shifts to C and D, connected by the black rod.

The motion of the rigid body composed of the two wheels plus the two rods can be deduced from the movement of the centres of the wheels (A, B, C, D) relative to the plane. For example, when rotation is around C-D, A and B will rise from the plane.

In MRI images the 'wheels' are represented by the circular surfaces of the femur in contact with the tibia (Fig. 3, bottom). Posterior translation of both 'wheels' (i.e., the femo-

ral condyles) with flexion would constitute 'roll-back' of the femur and posterior translation of only one 'wheel' indicates axial rotation (e.g., around the axis E in Figure 3, top).

Results

Correspondence between the appearance on MRI and on dissection (Fig. 2)

Using MRI, the bones and the contacting cartilage could be visualised simultaneously in sagittal section medially and laterally. The mediolateral position of the slices and the magnification were known. From this information the shapes and dimensions of the bones in mid-sagittal section, their positions relative to each other, the location of the centre of the circular femoral surfaces and the position and

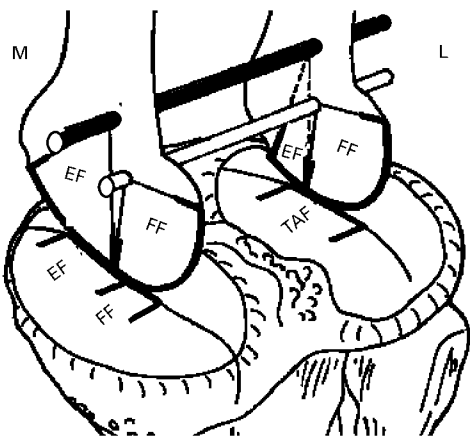
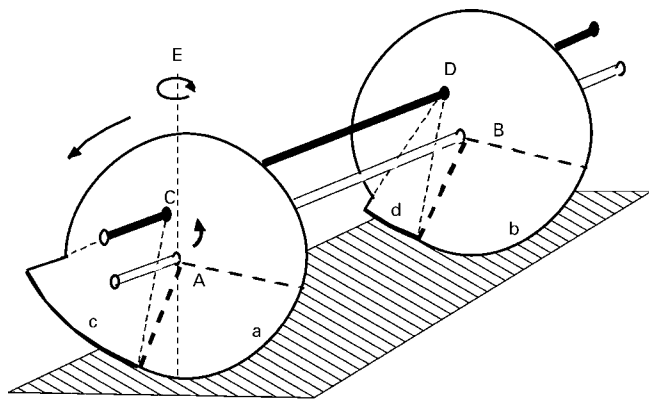


Fig. 3

Diagrams of two wheels (above) and MR images (as shown in Figure 2) rigidly connected by rods. For explanation see text.

extent of the contact areas could be determined with the capsule intact.

We were able to confirm that MRI gave a ‘true’ image compared with dissection. The data in this study are based on the MR images.

Shapes of the bones (Fig. 4)

Medial femoral condyle. Where it articulates with the tibia the surface of the medial femoral condyle is composed in sagittal section of the arcs of two circles: an anterior (the extension facet, EF) and a posterior (the flexion facet, FF). These arcs do not share a tangent at their point of junction producing a ‘kink angle’ between the adjacent radii of 11° .

The femur posterior to the posterior circular arc (PHF) articulates with the posterior horn in full flexion, never with the tibia. The anterior circle terminates anteriorly in a recess which articulates with the anterior horn in full extension.

Medial tibial condyle. This is composed of an anterior surface (the extension facet, EF) which slopes upwards and forwards by an average of 11° relative to a posterior, roughly horizontal surface. This facet is on average 17 mm in length. The anterior part of the horizontal surface (the flexion facet, FF), 10 mm in length, is in contact with the femur from $20^\circ \pm 10^\circ$ (varying from knee to knee) to 120° .

The posterior part of the horizontal surface (PHF), 15 mm in length, contacts only the posterior horn of the meniscus. At the anterior extremity of the EF the tibial surface slopes downwards to receive the anterior horn of the medial meniscus in extension (AHF).

Lateral femoral condyle. Like the medial condyle, this is circular posteriorly. It has a radius 1 mm smaller than the medial FF but has essentially the same average subtended arc (114° v 110°).

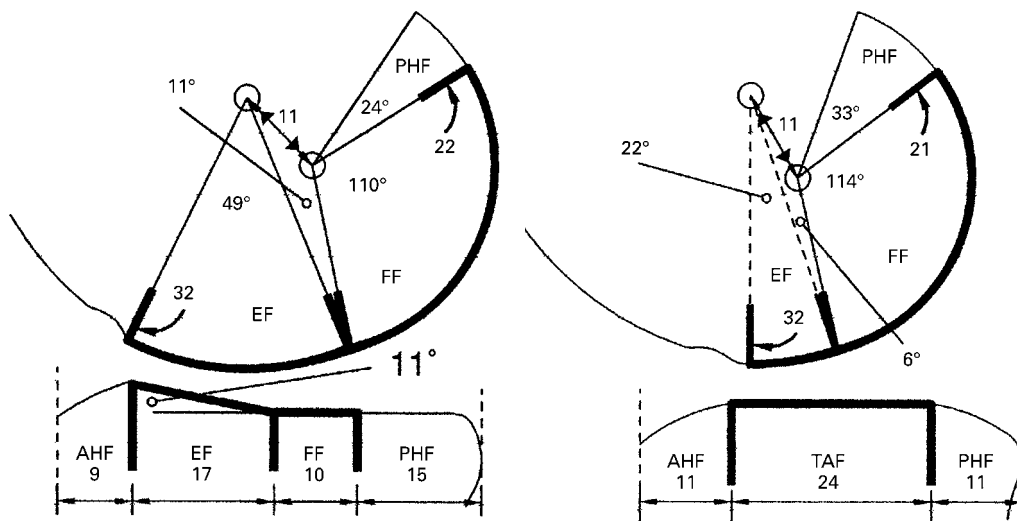


Fig. 4

Diagrams of sagittal sections of the medial (above) and lateral (below) tibiofemoral compartments to show the dimensions of the facets identified in Figure 2. Angles and lengths (mm) are given as means. The ranges depend on the size of the knee but the ratios of the radii of the femoral facets remain approximately constant regardless of size.

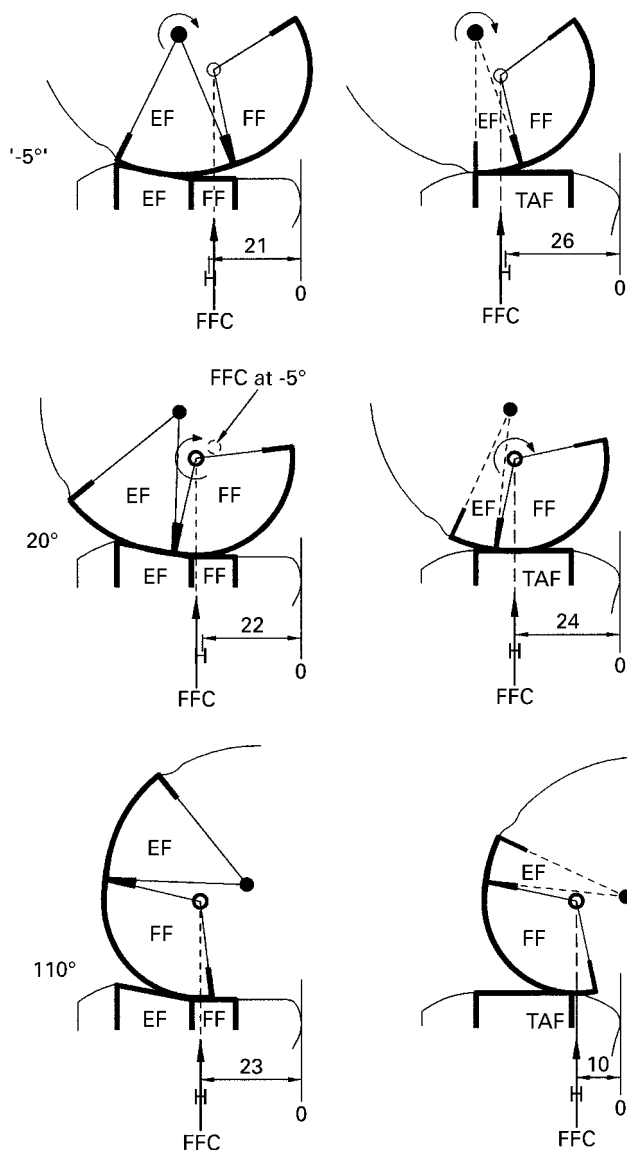


Fig. 5

Diagrams of sagittal sections of the tibiofemoral joint medially (above) and laterally (below) at -5° , 20° and 110° : compare with Figure 2. Numerals show the d1 distances (mm) at each position. The circular arrow indicates the facet centre around which rotation appears to be taking place. Note the change in the two contact areas.

In four knees there was a short segment of the articular surface between the FF and the anterior horn in full extension (i.e., by analogy with the medial side, 'EF') but its length was insufficient to be fitted to a circle with confidence. In two knees the anterior segment appeared to be absent. As a consequence the lateral articular surface as a whole was 6 mm shorter than the medial.

Posterior to the FF, the femur in full flexion is in contact only with the posterior horn. Anterior to the EF there is a recess for the anterior horn in extension which is more pronounced than that on the medial side.

Lateral tibial condyle. Only the central 24 mm of the

articular surface is in contact with the femur (tibial articular facet, TAF). It is relatively flat if sectioned near the lateral edge of the zone of direct tibiofemoral contact.

Anterior to the TAF the surface slopes downwards (AHF) to accommodate the anterior horn of the lateral meniscus in extension in conjunction with the corresponding recess in the femur. Posteriorly, the surface also slopes downwards (PHF) and articulates with the posterior horn beyond 90° .

Relative movements of the femur and tibia during flexion

The mean distances in six knees between the ipsilateral posterior tibial cortices and the femoral centres at certain angles of flexion are illustrated in Figure 5.

Medial compartment. The femoral FF was in contact with the tibial FF from 120° to 30° . Over this arc the femoral flexion facet centre (FFC) lay above the contact area. It did not move vertically relative to the tibia. The FFC moved forwards 2 mm between 120° and 110° but did not move thereafter. Thus tibiofemoral motion was almost pure sliding with the femur rotating around its FFC.

From 10° to full extension the femoral EF was in contact with the tibial EF and thus the tibial contact area lay about 8 mm anterior to that for the arc 30° to 120° . The femoral EFC did not move relative to the tibia. Rotation of the femur was around the EFC and tibiofemoral motion was pure sliding. This observation was confirmed by the finding that the FFC rose 2 mm away from the tibia between 10° and full extension, as has been observed previously.^{2,5}

From 30° to 10° the centre of rotation transferred from the femoral FF to the EF without anteroposterior motion of the condyle. The exact angle of transfer could not be determined because of the angulations between both the tibial and the femoral FFs and EFs, the compliant nature of the contacting surfaces, the lack of sufficiently small increments of arc between consecutive MR images, and variation between knees.

Thus the medial femoral condyle does not move anteroposteriorly between full extension and 110° in the unloaded cadaver knee; 2 mm of posterior movement may occur between 110° and 120° , but this is within the observer error. Although it does not move anteroposteriorly, the condyle does 'rock' between 30° and 10° from the posterior FF to the anterior EF. This phenomenon was noted by Weber and Weber² and called 'rocking' by Steindler.⁶

Lateral compartment. The movement of the lateral compartment differed from that of the medial as follows. At 110° and 120° , contact with the femur appeared to be shared between the tibia and the posterior horn. Over this arc the femoral FFC appeared to be 1 mm below its 90° position. From 90° to 10° the femoral FF was in contact with the tibia. From 10° to full extension (-5°) the EF, or the FF in the absence of the EF, was in contact. Over the arc 120° to -5° the femoral FFC moved forwards 19 mm relative to the tibia by rolling v sliding in the ratio 1.7:1; 15 mm of this displacement took place between 120° and 45° and 4 mm from 45° to -5° .

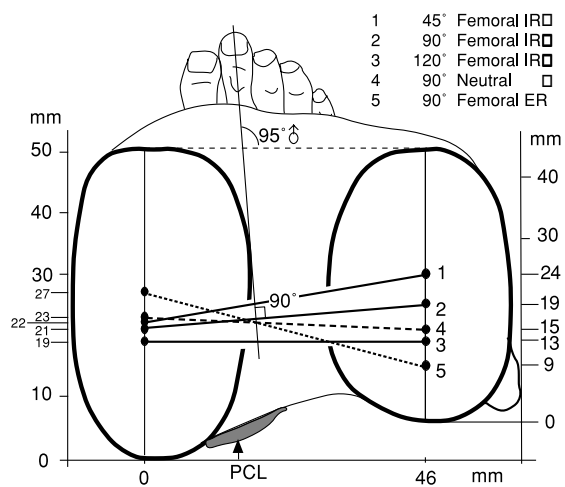


Fig. 7

Lines (as in Figure 6) representing the imaginary white rod in Figure 3 connecting the flexion facet centres of the femur medially and laterally at 45°, 90° and 120° with forced femoral external or internal rotation. Line 4 (90° neutral) is reproduced from Figure 6. Note that the intersection point of the lines representing the positions of the femoral condyles (i.e., connecting their FFCs) at 90° IR, neutral and ER lies lateral to the intersection point implied in Figure 6. This suggests that the axis of longitudinal rotation is not fixed.

the medial tibial condyle, level with the base of the medial tibial spine. This point can perhaps be taken to be the penetration point of the axis of longitudinal rotation.

Conclusions

We have been able to correlate MR images with the appearances at dissection and conclude that MRI can be used to determine the shapes of the bones and the movements between them in the intact unloaded cadaveric knee.

This finding raises the possibility of applying the same techniques to investigate the living knee both unloaded and loaded. In this connection, our observations need to be tested in the living knee using both MRI and another measurement technique. This could be done by reference to a prediction based on Figures 6 and 7, namely, that if the

femur were to be strongly internally rotated, or the tibia externally rotated, as the knee flexed, the knee could be flexed without accompanying longitudinal rotation. The work of Hill et al⁸ and of Karrholm et al⁹ can partly be seen in this context.

If this technique can be applied to the living knee and proves to be valid, we hope to use it to determine the location of the axes of rotation of the knee, the function of the ligaments, the location of the contact areas in normal and early osteoarthritic joints and perhaps to demonstrate abnormalities of movement after injury to ligaments.

We wish to thank Professor MUDr P. Strejc, DrSc, of the Institute of Forensic Medicine of Charles University, Prague for allowing the dissections and MUDr J. Danes, MD, Associate Professor of Radiology and Head of Department of Radiology, Charles University, Prague together with Dr J. Krasensky of Charles University, Prague for performing the MRI.

No benefits in any form have been received or will be received from a commercial party related directly or indirectly to the subject of this article.

References

1. Pinskerova V, Iwaki H, Freeman MAR. The shapes and relative movements of the femur and tibia in the unloaded cadaveric knee: a study using MRI as an anatomical tool. In: *Surgery of the knee*. In: Insall JN, Scott WN, eds. Third edition. Philadelphia: W B Saunders Co, 2000:in press.
2. Weber W, Weber E. Mechanics of the human walking apparatus (translated by Maquet P and Furlong R). Section 4: *On the knee*. Berlin: Springer Verlag. (First published as: *Mechanik der menschlichen Gehwerkzeuge*. Göttingen, 1836). 1992:75.
3. Strasser H. *Lehrbuch der Muskel- und Gelenkmechanik. III Band. Die untere Extremität*. Berlin: J. Springer, 1917.
4. Albrecht H. Zur Anatomie des Kniegelenkes. In: *Diss. Deutsche Zeits u Chirurgie*, 1876:433.
5. Kurosawa H, Walker PS, Abe S, et al. Geometry and motion of the knee for implant and prosthetic design. *J Biomech* 1985; 18:487.
6. Steindler A. *Kinesiology of the human body*. Springfield, Illinois: Charles C Thomas, 1955.
7. Yoshioka Y, Siu DW, Scudamore RA, Cooke TD. Tibial anatomy and functional axes. *J Orthop Res* 1989;7:132-7.
8. Hill PF, Vedi V, Williams A, et al. Tibiofemoral movement 2: the loaded and unloaded living knee studied by MRI. *J Bone Joint Surg [Br]* 2000;82-B:1196-8.
9. Karrholm J, Brandsson S, Freeman MAR. Tibiofemoral movement 4: changes of axial tibial rotation caused by forced rotation at the weight-bearing knee studied by RSA. *J Bone Joint Surg [Br]* 2000;82-B:1201-3.

A list of consulted publications concerning the normal knee will be found on the *Journal of Bone and Joint Surgery* web site (www.jbjs.org.uk) for this issue until 2002.